

PEDIATRICS®

OFFICIAL JOURNAL OF THE AMERICAN ACADEMY OF PEDIATRICS

Abusive Head Trauma: Judicial Admissions Highlight Violent and Repetitive Shaking

Catherine Adamsbaum, Sophie Grabar, Nathalie Mejean and Caroline Rey-Salmon

Pediatrics published online Aug 9, 2010;

DOI: 10.1542/peds.2009-3647

The online version of this article, along with updated information and services, is located on the World Wide Web at:

<http://www.pediatrics.org>

PEDIATRICS is the official journal of the American Academy of Pediatrics. A monthly publication, it has been published continuously since 1948. PEDIATRICS is owned, published, and trademarked by the American Academy of Pediatrics, 141 Northwest Point Boulevard, Elk Grove Village, Illinois, 60007. Copyright © 2010 by the American Academy of Pediatrics. All rights reserved. Print ISSN: 0031-4005. Online ISSN: 1098-4275.

American Academy of Pediatrics

DEDICATED TO THE HEALTH OF ALL CHILDREN™



Abusive Head Trauma: Judicial Admissions Highlight Violent and Repetitive Shaking

abstract

FREE

OBJECTIVE: Confessions are uncommon in abusive head trauma (AHT) cases, and there is debate over whether shaking alone can cause the injuries characteristic of AHT. The objective of this article is to correlate legal statements by perpetrators with medical documentation to offer insights into the mechanism of injury.

METHODS: In this retrospective observational study we examined forensic evidence from 112 cases referred for AHT over a 7-year period. We compared 29 cases in which a perpetrator confessed to violence toward the child with 83 cases in which there was no confession. Inclusion criteria were subdural hematoma (SDH) on computed tomography and perpetrator admission of a causal relationship between the violence inflicted and the child's symptoms. Groups were compared by using Student's *t* test for age and Fisher's exact test for gender, death, fractures, retinal hemorrhages, ecchymoses, symptoms, and SDH patterns. All medical records from birth to diagnosis, imaging studies, and written investigation reports were reviewed.

RESULTS: All confessions came from forensic investigations. There was no statistically significant difference between the 2 groups for any of the variables studied. Shaking was described as extremely violent (100%) and was repeated (55%) from 2 to 30 times (mean: 10) because it stopped the infant's crying (62.5%). Impact was uncommon (24%). No correlation was found between repeated shaking and SDH densities.

CONCLUSIONS: This unique forensic case series confirms the violence of shaking. The high frequency of habitual AHT is a strong argument for reporting suspected cases to judicial authorities and helps to explain the difficulty in dating the injuries. *Pediatrics* 2010;126:546–555

AUTHORS: Catherine Adamsbaum, MD,^{a,b} Sophie Grabar, MD, PhD,^{a,c} Nathalie Mejean, MD,^b and Caroline Rey-Salmon, MD^d

^aParis Descartes University, Paris, France; and ^bPediatric Radiology Department, St Vincent de Paul Hospital, ^cUnit of Epidemiology and Biostatistics, Cochin Hospital, and ^dMedico Judicial Unit, Hôtel-Dieu Hospital, Assistance Publique-Hôpitaux de Paris, Paris, France

KEY WORDS

abusive head trauma, subdural hematoma, child abuse

ABBREVIATIONS

AHT—abusive head trauma

CT—computed tomography

SDH—subdural hematoma

www.pediatrics.org/cgi/doi/10.1542/peds.2009-3647

doi:10.1542/peds.2009-3647

Accepted for publication May 21, 2010

Address correspondence to Catherine Adamsbaum, MD, Pediatric Radiology Department, St Vincent de Paul Hospital, 82 Avenue Denfert Rochereau, 75674 Paris Cedex 14, France. E-mail: c.adamsbaum@svp.aphp.fr

PEDIATRICS (ISSN Numbers: Print, 0031-4005; Online, 1098-4275).

Copyright © 2010 by the American Academy of Pediatrics

FINANCIAL DISCLOSURE: The authors have indicated they have no financial relationships relevant to this article to disclose.

Abusive head trauma (AHT) is a significant cause of severe brain injury in infants, and a leading area of controversy is whether shaking alone is sufficient to cause the characteristic injuries associated with AHT.^{1,2} Violent shaking is thought to subject the infant's head to acceleration-deceleration and rotational forces that create differential movement of the brain within the cranial compartment, which results in subdural, subarachnoid, and retinal hemorrhages often associated with hypoxic-ischemic injury.^{3,4} Brain computed tomography (CT) is often the first examination to be used for patients with acute injury for demonstrating the subdural hematoma (SDH) that provides one of the diagnostic clues.

Because perpetrators rarely admit to inflicting an injury, however, little is actually known about exactly what happened and when.⁵ Some reports have pointed to the potential for confusion in dating the brain injuries by radiologists, even those who are trained in pediatrics using both CT and MRI.⁶

Therefore, we analyzed detailed legal statements by perpetrators and correlated confessed histories with medical documentation to offer insights into the etiology of injury.

PATIENTS AND METHODS

This observational retrospective study was conducted over a 7-year period from January 2002 to May 2009. Among 112 patients diagnosed with AHT and referred to 39 different French courts for forensic investigation, we compared 29 cases (group A) in which a perpetrator confessed to violence toward the child with 83 cases (group B) in which there was no confession.

The inclusion criteria for the 112 patients were the presence of a SDH on CT scan and perpetrator conviction for AHT. The diagnosis of AHT was based on the presence of SDH with or without

traumatic skin lesions, skeletal fractures, or retinal hemorrhage in the absence of accidental trauma or metabolic or infectious pathology. The initial diagnosis of AHT was made by the pediatrician who reported the case to the social and judicial authorities. The diagnosis was later confirmed by the medical experts (Drs Adamsbaum and Rey-Salmon).

The selection criteria for group A was an admission by the perpetrator of a causal relationship between the violence inflicted and the child's symptoms. Perpetrators gave detailed descriptions of events, available in writing, during the various hearings. These 29 cases were selected for the study, and perpetrator statements were correlated with the patterns of SDH found on CT.

The infants' forensic and medical records from birth to the time of diagnosis were analyzed by the authors (Drs Adamsbaum and Rey-Salmon) as part of the judicial process. As forensic medical experts, they had access to the complete medical and judicial records. All available imaging studies (CT, MRI, standard radiographs, and ultrasound) were reviewed by a senior pediatric radiologist (Dr Adamsbaum).

For each patient, SDHs were categorized on CT as occurring in a single location or in multiple separate locations and as hyperdense (homogeneous or heterogeneous including mixed density) or hypodense. In case of multiple separate locations, SDHs were categorized as (1) having the same density in all sites, either all hyperdense or all hypodense, or (2) having different densities at different locations (eg, hyperdense deep SDH [interhemispheric and/or posterior fossa] associated with a hypodense lateral SDH (Fig 1).

The medical, biological, toxicological, and histologic data were analyzed by Drs Adamsbaum and Rey-Salmon. If necessary to draw a conclusion, they

could and did request missing medical records and conduct additional etiologic analysis (hemostasis, metabolic testing) with the judge's consent.

The details of all written investigation reports were carefully studied for each patient. In particular, we analyzed the number of violent acts reported, the delay between shaking and symptoms, the behavior of the child after the violence, the mechanism of the violence inflicted, and the indication of head impact. When the perpetrator reported "multiple episodes of shaking per week," we counted it as 2 episodes per week.

A senior forensic pediatrician (Dr Rey-Salmon) performed medical examinations on all surviving children at the time of the judicial proceedings.

Groups A and B were compared by using Student's *t* test for age and Fisher's exact test for other qualitative variables such as demographics, symptoms, and lesion characteristics at presentation (gender, death, isolated vomiting, seizures, loss of consciousness, cardiopulmonary arrest, behavior changes, strabismus, presence of fractures, retinal hemorrhages, ecchymoses, and SDH patterns). A *P* value <.05 was used to denote statistical significance.

RESULTS

Description and Comparison Between the 2 Groups

Of 112 patients, 109 had 1 or more of the following, in addition to the SDH: previous or current ecchymoses; previous or current fractures; and current retinal hemorrhages (Table 1).

In 83 of 112 cases (group B), despite evidence of AHT, there was no admission of a causal relationship between the violence inflicted and the child's symptoms. In 19 of these cases, a perpetrator reported having shaken the child violently to revive him or her from

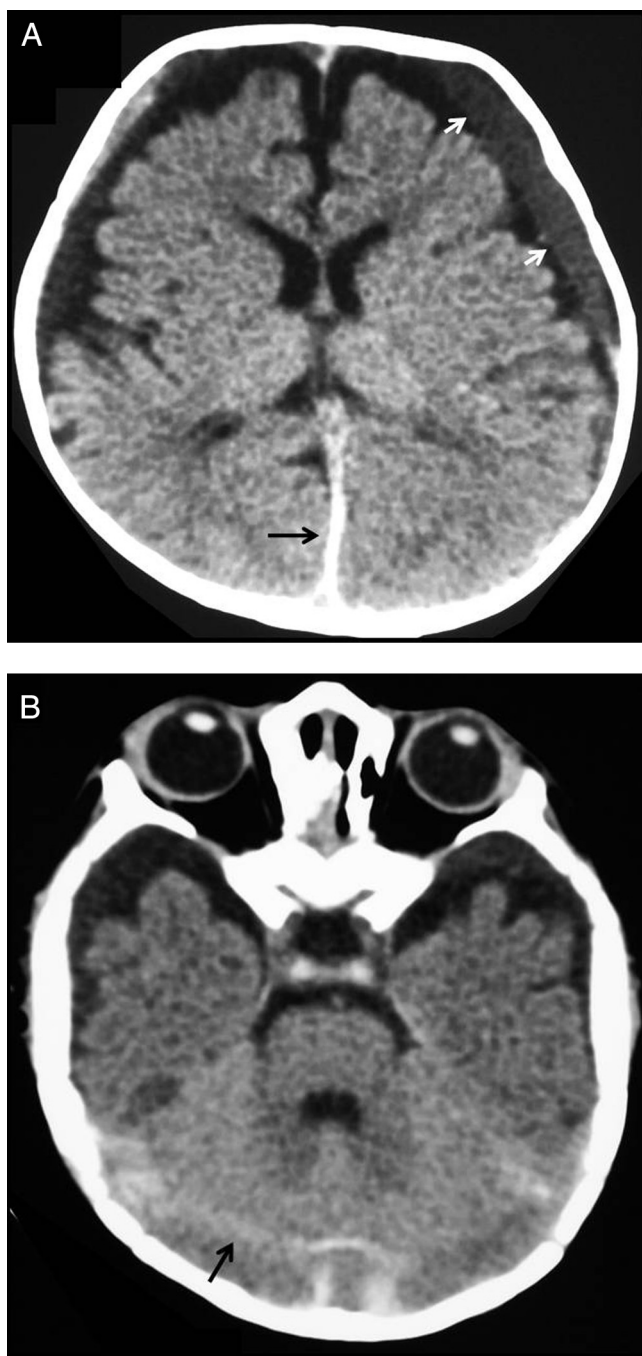


FIGURE 1

CT images of a 5-month-old infant who suffered multiple shakings over more than 1 month. Multifocal SDHs of different densities can be seen in separate locations. A, Lateral hypodensity (white arrows) associated with interhemispheric hyperdensity (black arrow); B, tentorium cerebelli hyperdensity (black arrow).

an apparent life-threatening event; in 28 cases, a minor accident was reported (short-distance fall or impact); and in 36 cases, the child's entourage did not report any particular event during the observation period.

The overall male-to-female gender ratio was 3.15 (85 boys, 27 girls). The mean age was 5.6 ± 4.8 months (range: 3 weeks to 31 months, excluding 3 outliers older than 40 months [84 and 42 months in group A and 48 months in group B]).

In the 112 patients, there were 30 (27%) fractures, 53 (47%) ecchymoses, and 99 retinal hemorrhages (88%). The most frequent symptom at presentation was seizure, which occurred in 69 of the 112 (62%) patients. SDHs were located in multiple sites in 111 of the 112 children (99%). They were found interhemispherically ($n = 107$ [95.5%]), in the tentorium cerebelli ($n = 96$ [86%]), and in the right or left lateral spaces ($n = 112$ [100%]). They were hyperdense at all sites in 39 (35%), hypodense in all sites in 2 (2%), and hypodense in lateral locations and hyperdense in deep locations in 71 (63%) of these 112 children.

There was no statistically significant difference between the groups with and without detailed confessions for any of the variables studied (ie, age, gender ratio, number of deaths, main symptoms, presence of fractures, ecchymoses, retinal hemorrhages or SDH pattern [all $P > .05$] [Table 1]).

Population With Detailed Confessions ($N = 29$)

There were 7 girls and 22 boys (gender ratio: 1:3) aged 1 month to 7 years at the time of diagnosis (mean age: 8 months). Of these children, 27 (93%) were younger than 1 year. Nine infants (31%) had died.

In 23 of the 29 cases (79%), the major clinical symptoms that led to CT were acute, mainly seizures ($n = 19$ [65.5%]). Other symptoms included vomiting ($n = 2$), anorexia ($n = 1$), hip trauma ($n = 1$), strabismus ($n = 1$), and abnormal tonic-ity ($n = 1$) (Table 2).

Eleven infants (38%) had multiple ecchymoses ($n = 10$, including 8 cases in nonambulatory infants and 2 cases of atypical locations [such as skull, face, or trunk] in ambulatory children) or hematoma of the tongue ($n = 1$). Two children had a weight for age below -3 SDs at the time of diagnosis. Two

TABLE 1 Comparison Between Group A (Full Confessions) and Group B (Without Full Confessions)

	Group A (N = 29)	Group B (N = 83)	P ^a
Age, mean \pm SD, mo ^b	4.7 \pm 2.9	6 \pm 5.3	.21
Gender ratio, male/female	22/7	63/20	1.00
Death, n (%)	9 (31.0)	16 (19.2)	.19
Isolated vomiting, n (%)	2 (6.9)	8 (9.6)	1.00
Seizures, n (%)	19 (65.5)	50 (60.2)	.66
Loss of consciousness, n (%)	2 (6.9)	7 (8.4)	1.00
Cardiopulmonary arrest, n (%)	2 (6.9)	12 (14.4)	.51
Behavior changes, n (%) ^c	2 (6.9)	2 (2.4)	.27
Strabismus, n (%)	1 (3.4)	0 (0.0)	.26
Macrocrania, n (%)	0 (0.0)	2 (2.4)	1.00
No neurologic signs, n (%)	1 (3.4)	2 (2.4)	1.00
Fractures, n (%)	11 (37.9)	19 (22.9)	.11
Skull fracture, n (%)	3 (10.3)	7 (8.4)	.72
Ecchymoses, n (%)	11 (37.9)	42 (50.6)	.23
Retinal hemorrhage, n (%)	24 (82.7)	75 (90.3)	.19
SDH, multiple separate locations, n (%)	29 (100)	82 (98.7)	1.00
Hyperdensity in all sites, n (%)	11 (37.9)	28 (33.7)	.82
Hypodensity in all sites, n (%)	2 (6.9)	0 (0.0)	.07
Hypodense lateral/hyperdense deep sites, n (%)	16 (55.1)	55 (66.2)	.32

Shown are symptoms and signs at presentation.

^a Student's *t* test for age; Fisher's exact test for other variables.

^b SD excluding 3 outliers aged >36 months (84, 42 months in group A, 48 months in group B).

^c Including anorexia (*n* = 1, group A) and irritability (*n* = 1 group A, *n* = 2 group B).

children had been born prematurely (at 31 and 34 weeks' gestation).

Previous signs of maltreatment were found in the medical records of 8 children (27%). These signs were ecchymoses in nonambulatory children (*n* = 5) noticed from 1 week to 2 months before the acute episode, elbow fracture 5 months before the acute episode (*n* = 1), and a loss of weight under -3 SDs for age (*n* = 1). In none of these cases did these signs lead to suspicion of the diagnosis.

Ophthalmologic examination was performed on all infants, after death in 2 cases (patients 5 and 14). Funduscopy results were considered normal in 5 cases (17%) and revealed retinal hemorrhages that were bilateral in 22 cases (76%) and unilateral in 2 cases.

All but 1 of the infants had a skeletal survey; 11 (38%) had fractures at the time of diagnosis, including 3 skull fractures (Table 1). Five children had healing rib fractures that appeared to be multiple in 4 of them and single in 1 patient (patient 29); 2 children had vertebral fractures (lumbar crush frac-

tures at L2 and L3 in patient 21 and transverse fracture of L3 together with rib fractures in patient 5). Of the 9 patients with multiple fractures, 2 presented age-different fractures (healing fracture of the clavicle and recent fracture of the femoral shaft in patient 2 and rib fracture, classic metaphyseal lesions [CMLs] of the knees and ankles, and acromion fracture in patient 17). CMLs of the knees, ankles, and elbows were seen in 3 patients (patients 17, 19, and 28) at a healing stage (periosteal appositions), and another (patient 14) presented a deformity of the distal part of the right humerus that appeared traumatic in origin. In patient 28, the distal CML of the tibia was associated with a healing spiral tibial fracture.

All infants underwent noncontrast CT scanning (inclusion criterion). The time between admission and CT ranged from 6 hours to 4 days, depending on the infant's clinical status.

In all cases, CT revealed at least 2 separate locations of SDHs. They were found in interhemispheric (27 of 29 [93%]), tentorium cerebelli (24 of 29

[83%]), and lateral right or left (29 of 29 [100%]) spaces.

The SDHs had the same density in all sites in 13 patients, either all hyperdense (homogeneous or heterogeneous) (*n* = 11; Figs 2 and 3) or all hypodense (*n* = 2). In the remaining 16 of 29 patients, the SDHs had different densities at different locations: hyperdense deep SDH (interhemispheric and/or posterior fossa) associated with a hypodense lateral SDH (Fig 1).

In addition, 22 of 29 patients presented with focal or diffuse parenchymal hypodensities on the initial CT scan.

When performed (*n* = 14), MRI confirmed the SDHs in all cases. All but 1 of the patients who underwent diffusion-weighted sequences (*n* = 12) exhibited hypoxic-ischemic injury patterns (Fig 3).

Perpetrator Statements

No statement was obtained during hospitalization. All confessions came during police custody or the judicial investigation, weeks or months after the diagnosis. The perpetrator was the father or stepfather in 13 cases (45%), the mother in 8 cases (27%), the child minder in 6 cases (21%), a teenaged brother in 1 case (patient 12), and both the mother and stepfather in the case of 1 young boy (patient 5, 7 years old) (Table 3).

All of the perpetrators described having shaken the infant violently. All the confessions included terms that denoted violence, and all the authors admitted the violence of their acts in response to the corresponding question from the court or the police inquiries. All children were taken under the arms and shaken violently, sometimes with verbal abuse. In 5 cases, a final violent impact of the infant's head on a bed was described.

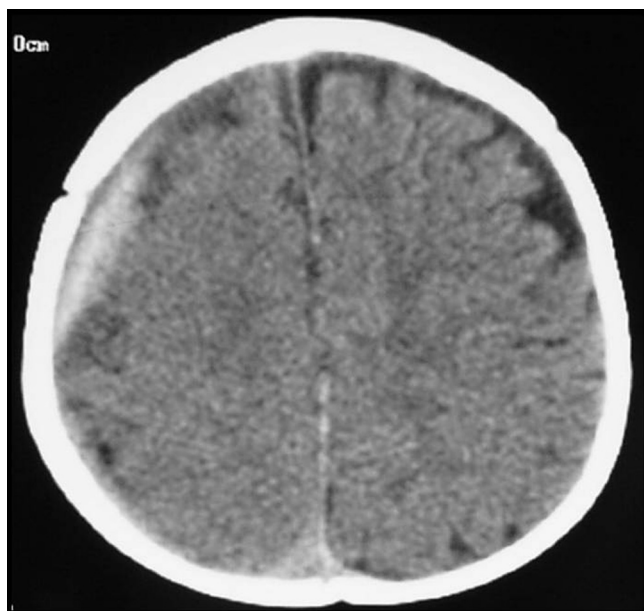The shaking was described as a single violent episode in 13 cases (45%). In 4

TABLE 2 Characteristics of the Population (*N* = 29)

Patient No.	Gender	Age, mo	Symptom at Diagnosis	Retinal Hemorrhage	Skin Lesions	Fracture	Other	Previous Injury
1	M	2	Vomiting	0	Ecchymoses	Ribs	Loss of weight	Loss of weight
2	M	1	Hip trauma	0	0	Clavicle, femur	0	0
3	M	6	Seizures	Bilateral	0	0	0	0
4 ^a	M	6	Seizures	Bilateral	Ecchymoses	Skull	0	0
5 ^a	M	84	Coma	ND	Ecchymoses, burns	Ribs, lumbar transverse	Loss of weight	Ecchymoses
6	M	1	Seizures	Bilateral	Ecchymoses	0	0	0
7 ^a	M	6	Seizures	Bilateral	Ecchymoses	0	0	0
8 ^a	F	2	CP arrest	Bilateral	Ecchymoses	0	Premature: 31 wk gestation	0
9	F	3	Anorexia	Bilateral	0	0	0	0
10	M	8	Seizures	Left	0	0	0	0
11	M	4	Seizures	Bilateral	0	0	0	0
12	M	6	Seizures	Bilateral	0	Ribs	0	Ecchymoses
13	F	5	Seizures	Bilateral	0	0	0	Ecchymoses
14 ^a	M	42	Coma	ND	Ecchymoses	Elbow, skull	0	Fracture
15	M	5	Seizures	Bilateral	Ecchymoses	0	0	Ecchymoses
16	M	5	CP arrest	Bilateral	0	0	0	Ecchymoses
17 ^a	M	2	Seizures	Bilateral	Ecchymoses	Ribs, metaphyses	0	0
18	M	5	Seizures	Bilateral	0	0	0	0
19	F	4	Hypotony	0	0	Metaphyses, skull	Premature: 34 wk gestation	Ecchymoses
20	M	6	Seizures	Bilateral	0	0	0	0
21	M	2	Seizures	Bilateral	0	Vertebra	0	0
22	M	10	Strabismus	Bilateral	0	0	0	0
23	F	6	Seizures	Bilateral	0	0	0	0
24 ^a	M	1	Seizures	Bilateral	Ecchymoses	0	Tongue hematoma	0
25 ^a	F	1	Seizures	0	0	0	0	0
26 ^a	M	11	Seizures	Bilateral	0	0	0	0
27	M	11	Seizures	Bilateral	0	0	0	0
28	M	3	Seizures	0	0	Tibia (shaft and metaphysis)	0	0
29	F	4	Vomiting	Right	0	Rib	0	0

M indicates male; F, female; CR, cardiopulmonary; ND, not determined.

^a Died.

**FIGURE 2**

CT image of a 6-month-old infant who was shaken several times per week for more than 2 months. Right lateral and interhemispheric hyperdense SDHs can be seen, as associated with a mild mass effect on the right side.

cases, the perpetrator reported symptoms immediately after the shaking. In 6 cases, the author put the child to bed immediately after the shaking and only discovered the presence of abnormal symptoms 1.5 (*n* = 4) and 3 hours (*n* = 2) later. In 3 cases, the time delay was unclear but was <24 hours.

Repeated episodes of violent shaking were described in 16 cases (55%). The number of admitted shaking episodes ranged between 2 and 30 (mean: 10). Shaking was described as habitual (ie, daily) for several weeks or months in 6 cases. In the latter, the minimum number of episodes was estimated to be between 10 and 30. In 3 cases, the perpetrator did not give details about the number

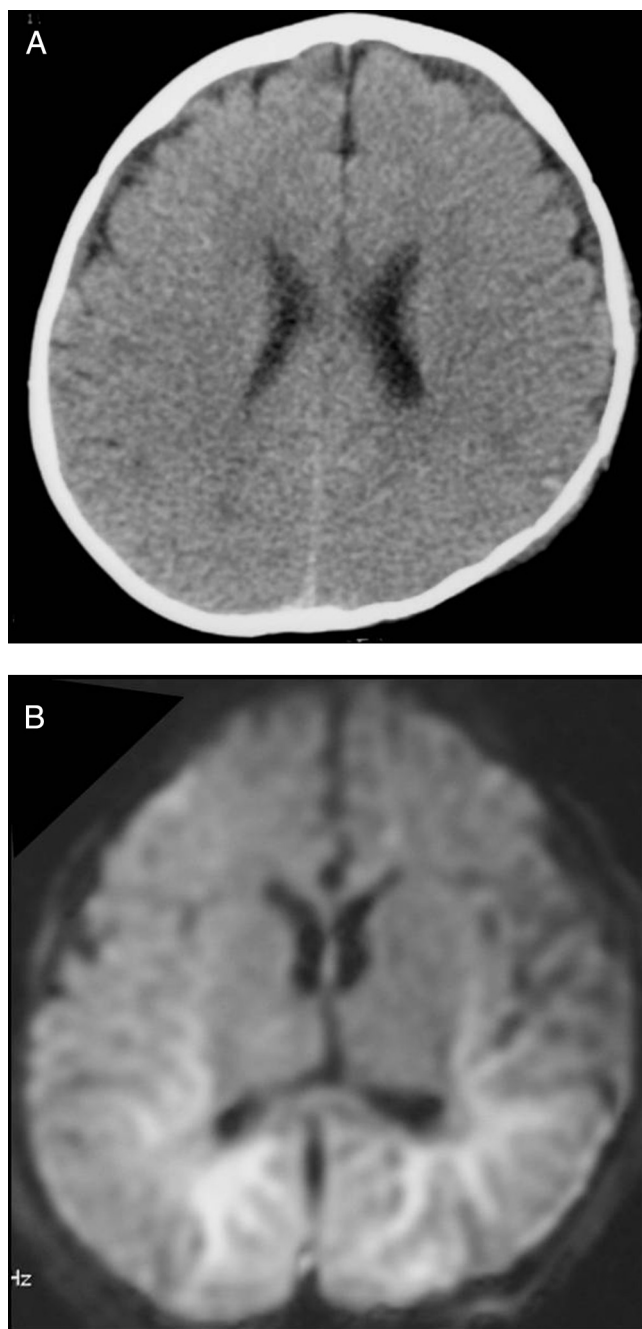


FIGURE 3

Images of a 6-month-old infant who was shaken violently several times per week over 3 months. A, A CT scan shows SDH marked by subtle interhemispheric hyperdensity. Brain edema probably masks a pericerebral hypodense SDH. B, MRI (diffusion-weighted sequence) shows bilateral hyperintensities within temporo-parieto-occipital white matter related to a hypoxic-ischemic pattern. Both SDHs and hypoxic-ischemic lesions were confirmed during an autopsy and histology.

of episodes. Ten perpetrators described an immediate period of exhaustion, in which the child would “go to sleep after the shaking.” All of these perpetrators reported that shaking was repeated because it

stopped the infant’s crying, but they did not give additional information about the final episode of shaking. The offender could not remember exactly how long the episodes of violence had been occurring.

Below are some excerpts from perpetrator statements obtained during police or judicial investigations.

“I shook him for more than 2 months, several times a week at arm’s length.”

“I was feeling really bad, I was at the end of my rope from not sleeping. I shook him several times a week, I don’t know exactly, always at night.”

“I took her by the shoulders; I shook her and I yelled.”

“I was holding my daughter under the arms, and I shook her. Her head wasn’t being held and was snapping back and forth.”

“I thought I might have dislocated his shoulder when I shook him.”

“I didn’t want to choke him, but I wanted him to stop crying. I picked him up and I shook him; I threw him on the bed and he bounced on the sheet.”

“When I can’t calm my son I take him under the arms and, holding him firmly, I move him forward and back; I shook him several times without realizing my own strength. His head snapped back and forth from time to time. After I shake him like that, he’s tired and goes to sleep...”

“I shake him almost every day when I’m watching him; I can’t tell you how many times; I started when he was about 4 months old.”

“He was crying; it drove me crazy, I shook him ... maybe 10 times, and threw him on the sofa.”

“Once or twice I’ve held him at arm’s length and shaken him; I’ve blown a fuse; over more than a month I’ve shaken him several times.”

“I had fits of anger. She would cry; sometimes, when she did that, I’d shake her ... I got worked up and twisted her arm; I was slapping her hard for more than 2 months.”

“I hold him up in front of my face; I swing him back and forth; I’m not holding his head ... because I’m exasperated, my movements are sometimes rough.”

“I was holding him under the arms; I jostled him; I didn’t shake him for long; I took him and put him down hard. There were at least 3 episodes of shaking in a little over a month; the last was harder. I had to hold him under the armpits while I was shaking him because he’s too heavy (5 kg).”

“I shook her so she’d be quiet, it lasted maybe 5 minutes; I was exasperated; I shook her up and down, in front of me, without holding her against me; I was shaking her hard; I was crying just like she was, and I was worked up.”

TABLE 3 Imaging and Statements (*N* = 29)

Patient No.	Perpetrator	Delay of Symptoms	Impact	Shakings	Multifocal SDH Density	MRI, Day No.	Parenchyma	Autopsy/Histology
1	Father	—	—	Multiple	Hyperdense and hypodense	—	Normal	0
2	Father	—	—	Multiple	Hyperdense and hypodense	—	Porencephaly	0
3	Child minder	—	—	>15 over 2 mo	Hyperdense	—	Hypoxic ischemic	0
4 ^a	Mother	—	—	>30 over 3 mo	Hyperdense	2	Hypoxic ischemic	SDH
5 ^a	Mother and stepfather	—	yes	Single	Hyperdense	—	Hypoxic ischemic	SDH, hypoxic ischemic
6	Father	Immediate	—	Single	Hyperdense and hypodense	—	Hypoxic ischemic	0
7 ^a	Mother	—	—	Single	Hyperdense	—	Hypoxic ischemic	SDH, contusions, hypoxic ischemic
8 ^a	Father	—	—	At least 2 over 1 month	Hyperdense and hypodense	—	Hypoxic ischemic	SDH, cervical cord hematoma
9	Mother	—	—	At least 4 over 2 mo	Hyperdense and hypodense	—	Normal	0
10	Child minder	<1.5 h	—	Single	Hyperdense	5	Hypoxic ischemic	0
11	Father	Immediate	—	Single	Hyperdense	—	Hypoxic ischemic	0
12	Teenaged brother	—	yes	3 times	Hyperdense and hypodense	13	Hypoxic ischemic	0
13	Father	—	—	Multiple	Hyperdense and hypodense	—	Hypoxic ischemic	0
14 ^a	Mother	Immediate	yes	Single	Hyperdense	—	Hypoxic ischemic	SDH, contusions
15	Father	—	—	>30 over 1 mo	Hypodense	—	Normal	0
16	Father	Immediate	—	Single	Hyperdense and hypodense	1	Hypoxic ischemic	0
17 ^a	Father	—	yes	At least 10	Hyperdense and hypodense	3	Hypoxic ischemic	SDH, hypoxic ischemic
18	Father	—	—	At least 2 over 1 mo	Hyperdense and hypodense	—	Normal	0
19	Mother	—	—	>15 over 2 mo	Hypodense	2	Hypoxic ischemic	0
20	Child minder	—	—	At least 3	Hyperdense and hypodense	1	Hypoxic ischemic	0
21	Mother	<3 h	—	Single	Hyperdense and hypodense	0	Hypoxic ischemic	0
22	Stepfather	—	—	>10	Hyperdense and hypodense	2	Normal	0
23	Child minder	<1.5 h	—	Single	Hyperdense and hypodense	2	Hypoxic ischemic	0
24 ^a	Father	—	—	Single	Hyperdense	—	Hypoxic ischemic	SDH, contusions, edema
25 ^a	Mother	<1 h	—	Single	Hyperdense and hypodense	—	Hypoxic ischemic	0
26 ^a	Child minder	<1 h	yes	Single	Hyperdense	5	Hypoxic ischemic	SDH
27	Child minder	<3 h	—	Single	Hyperdense	0	Hypoxic ischemic	0
28	Father	—	—	3 over 1 mo	Hyperdense	2	Hypoxic ischemic	0
29	Mother	—	—	3 over 3 wk	Hyperdense and hypodense	1	Normal	0

— indicates that data were not available.

^a Died.

Correlations Between Perpetrator Statements and Head Imaging

Five perpetrators admitted head impact, and the child died in 4 of these cases. One of these children (patient 14) was found to have a skull fracture. Two other patients (patients 4 and 19) had a skull fracture, although there was no admission of head impact, which suggests incomplete confessions (Table 3).

No correlation was found between repetitive shaking and SDH densities.

Sixteen patients were reported to have had recurrent multiple shakings. SDHs had different densities at different lo-

cations in 11 of these infants (Fig 1) and had the same density in 5. Of the latter, 3 had hyperdense homogeneous or heterogeneous SDHs (Figs 2 and 3) and 2 had hypodense SDHs.

On the other hand, 16 patients had SDHs of different densities at different locations. In these cases, 11 of the perpetrators admitted multiple shaking episodes, and 5 reported only a single violent shaking episode.

Thirteen patients exhibited SDHs of the same density in all sites: all hyperdense (*n* = 11) or all hypodense (*n* = 2). Five of the perpetrators clearly described repeated shakings. Among

these cases, the SDHs were all hypodense in 2 cases.

Pathology data were available in 8 of 9 fatal cases and confirmed the presence of SDHs in all of the patients. Contusions and/or hypoxic-ischemic injuries were described for 6 patients without details about dating. Of importance is the presence of a cervical hematoma in patient 8, who did not undergo MRI.

DISCUSSION

To the best of our knowledge, this is the only case series with descriptions of confessions of forensic origin in the

medical literature. Confessions are uncommon. Not only do perpetrators fail to acknowledge the event, but the duration of the judicial proceedings after reporting renders access to statements impossible outside of an expert medical opinion. Our results confirm the difficulties, because this series of 29 cases was the fruit of 7 years' analysis of 112 medicolegal cases of AHT.

The group of 29 infants studied displayed the classic features of AHT: multiple sites of SDHs and hypoxic-ischemic lesions, male predominance, young age, and acute signs or history of poor feeding, vomiting, or skeletal injuries.^{3,7-11} There was no significant difference in mean age, gender ratio, frequency of mortality, main symptoms at presentation (vomiting, loss of consciousness, cardiopulmonary arrest, etc), ecchymoses, fractures, or retinal hemorrhages between the group with full confessions ($n = 29$) and the group without full confessions ($n = 83$) (Table 1). Because of the retrospective and unique character of the study, no power calculations were performed before beginning the study. The number of children included in the study, therefore, may have been too small to detect differences between the 2 groups. However, if these 2 groups were similar, the causal mechanism may well have been the same despite the incomplete or absent confessions. For the purposes of this study, "confession" was defined as the admission by a perpetrator of a causal relationship between the violence inflicted and the child's symptoms. In the group without confessions, admissions were of violent shaking in an attempt to revive the child from an apparent life-threatening event or minor accident (57%) or even no particular event (43%). Because detailed confessions are uncommon, it is important to focus on the information provided.

Analysis of this series of confessions highlights several basic points. First, it confirms the violence of the causal acts and, thus, the relevance of the American Academy of Pediatrics' definition: "The act of shaking leading to [AHT] is so violent that individuals observing it would recognize it as dangerous and likely to kill the child."³ In our series, all of the perpetrators who confessed (100%) described a violent and inappropriate attack that resulted from fatigue and irritation connected with the infant's crying.

One of the most important points in this article is the role of shaking in the etiology of these injuries. As the excerpts show, all of the perpetrator statements obtained during judicial or police investigations (containing written, detailed descriptions of events) described shaking. This unique series of confessions confirms the pathogenic nature of shaking in and of itself, even without final impact.¹² We have provided excerpts from perpetrator statements to avoid interpretation.¹³

On the basis of the presence of a skull fracture or perpetrator statement, there was head impact in only a few of the cases (7 of 29). Of interest is that 2 children had a skull fracture without the perpetrator describing head impact, which suggests that the confessions were incomplete.

The main limitation of the study is that perpetrator admissions are not scientific evidence; however, they provide information that is invaluable to our understanding. Even in this context of written legal statements, some admissions are likely to be incomplete or minimized. Likewise, a single admitted episode of shaking may only be a part of the story.

The admissions of the perpetrators highlight the frequency of repeated violent shaking (55%). Shaking may be

repeated on a daily basis over several weeks or months, as 6 of the perpetrators clearly reported. The estimated number of episodes ranged from 10 to 30 episodes of shaking, which is probably an underestimation, because we have assumed only 2 episodes per week when the perpetrator reported "several times" of shaking per week. Knowing that shakings are often multiple and repeated over time helps explain why it is inaccurate to date the lesions with brain imaging, CT, or even MRI.⁶

Because there was no association between SDH densities and the number of episodes of abuse, it seems clear that CT should not be used to determine chronicity of abuse. An all-hyperdense multifocal SDH was seen in 31% of admitted repetitive shakings. A hyperdense SDH can be homogeneous or heterogeneous (mixed density pattern) and may vary from one day to another.⁶ Although our results did not reveal any statistically significant association between the SDH patterns on CT and the admissions of single or multiple shakings, this could be a result of the study's lack of power. A subtle hypodense SDH pattern may also be the result of AHT with habitual repetitive, violent shaking, as 2 of the statements clearly indicated. It is important to stress that a hypodense SDH may be misinterpreted as benign "external hydrocephalus." Thus, this pattern should prompt clinicians to look for bruises and/or previous unexplained symptoms.⁹ In particular, a number of injuries might have been prevented if the significance of bruising in these young infants had been recognized.

Why is shaking so often repetitive? The perpetrators' statements offer an explanation. Shaking is effective because it stops the infant's crying, and he or she "goes to sleep after being shaken" (62.5%). This exhaus-

tion reported after shaking may well be considered an immediate symptom, similar to those cited in previous reports.^{12,14} In our study, in 4 cases of single shaking, the perpetrator clearly indicated immediate symptoms after the shaking. In the other cases, the timing was unclear because the child was put to bed immediately after the shaking, with symptoms discovered after a delay that was usually <3 hours. This period of “exhaustion” that occurred immediately after shaking may be a symptom of hypoxic-ischemic injuries in some of the patients. To date, hypoxic-ischemic injury is not completely understood and is probably a result of complex factors (concussion, edema, axonal and/or brainstem injury, concomitant strangulation, etc) or other causes of global neurologic dysfunction that may result from shaking.^{15–17}

No admission was made during the infants’ hospitalization. All the declarations came from legal statements (police custody and investigations), sometimes after a subsequent forensic investigation. Although Starling et al¹⁴ reported cases in which the shaking was admitted in the hospital, it seems crucial that the medical corps quickly report any suspicion of AHT to the social and judicial authorities to break the vicious cycle of shaking. The main goal is to take appropriate action with regard to the offender and prevent new episodes of violence against

the child, siblings, or even other children in the neighborhood.^{18,19} With early identification of shaken infants, families can be offered adequate social interventions.

Physicians’ decision to report may conflict with their duty to maintain the confidentiality of the doctor-family relationship.²⁰ However, we have not only an ethical but also a legal responsibility to report suspected abuse that supersedes any confidentiality obligation.

In France, failure to act in cases in which one suspects child abuse is considered a violation of the “duty to rescue.”²¹ However, physicians are not responsible for determining who injured the child; that is the job of the police.

This case series confirms that the majority of the perpetrators are fathers and stepfathers (14 of 29).^{22,23} This should be interpreted with caution, however, because we do not know whether such perpetrators are violent more often or simply confess more often.

Collaboration between radiologists and clinicians is crucial for both diagnosis and prognosis in cases of child abuse.²⁴ Expert conclusions often have a decisive role in court decisions, and a recent study focused on the wide variability between experts.²⁵ Knowledge of the highly repetitive nature of AHT, the difficulty in dating lesions, and confirmation of the violent shaking involved should all help with objective interpretation.

Another limitation of this retrospective study is that a number of patients did not undergo MRI in the acute period. In France, brain CT is often the initial examination used for patients with acute injury or illness, and MRI is not yet routinely performed if the diagnosis of AHT is not in doubt and if there is no question of surgery. There are several reasons for this, including limited availability of MRI in some hospitals and unstable condition of the child in the ICU.

CONCLUSIONS

AHT is frequently related to violent shaking, the repetitive nature of which—explained by the immediate effect of shaking on crying—has been underestimated. The high frequency of habitual AHT is a strong argument for reporting suspected cases to judicial authorities and helps explain the difficulty in dating the injuries. Because CT has limitations, we recommend using MRI in addition to detect acute hypoxic-ischemic injuries as soon as the diagnosis of AHT is suspected.^{4,5,26} These data should help better protect infants suspected of having AHT, and thorough police investigation will best determine the chronicity of abuse.

ACKNOWLEDGMENTS

We thank O. Delattre, MD, PhD, for critical reading, N. Friedman and A. Dehaye for English review, and P. Zerbini for manuscript preparation.

REFERENCES

1. Gilliland MG, Folberg R. Shaken babies: some have no impact injuries. *J Forensic Sci.* 1996;41(1):114–116
2. Duhaime AC, Gennarelli TA, Thibault LE, Bruce DA, Margulies SS, Wiser R. The shaken baby syndrome: a clinical, pathological, and biomechanical study. *J Neurosurg.* 1987;66(3):409–415
3. American Academy of Pediatrics, Committee on Child Abuse and Neglect. Shaken baby syndrome: rotational cranial injuries—technical report. *Pediatrics.* 2001;108(1):206–210
4. Zimmerman RA, Bilaniuk LT, Farina L. Nonaccidental brain trauma in infants: diffusion imaging, contributions to understanding the injury process. *J Neuroradiol.* 2007;34(2):109–114
5. Stoodley N. Non-accidental head injury in children: gathering the evidence. *Lancet.* 2002;360(9329):271–272
6. Vezina G. Assessment of the nature and age of subdural collections in nonaccidental head injury with CT and MRI. *Pediatr Radiol.* 2009;39(6):586–590
7. Geddes JF, Plunkett J. The evidence base for shaken baby syndrome. *BMJ.* 2004;328(7442):719–720
8. Hobbs CJ, Biló RAC. Nonaccidental trauma: clinical aspects and epidemiology of child abuse. *Pediatr Radiol.* 2009;39(5):457–460
9. Kleinman PK. *Diagnostic Imaging of Child Abuse.* 2nd ed. St Louis, MO: Mosby; 1998

10. Barlow KM, Gibson RJ, McPhillips M. Magnetic resonance imaging in acute non-accidental head injury. *Acta Paediatr*. 1999; 88(7):734–740
11. Tung GA, Kumar M, Richardson RC, Jenny C, Brown WD. Comparison of accidental and nonaccidental traumatic head injury in children on noncontrast computed tomography. *Pediatrics*. 2006;118(2):626–633
12. Biron D, Shelton D. Perpetrator accounts in infant abusive head trauma brought about by a shaking event. *Child Abuse Negl*. 2005; 29(12):1347–1358
13. Leestma JE. Case analysis of brain-injured admittedly shaken infants: 54 cases, 1969–2001. *Am J Forensic Med Pathol*. 2005; 26(3):199–212
14. Starling SP, Patel S, Burke BL, Sirotnak AP, Stronks S, Rosquist P. Analysis of perpetrator admissions to inflicted traumatic brain injury in children. *Arch Pediatr Adolesc Med*. 2004;158(5):454–458
15. Geddes JF, Vowles GH, Hackshaw AK, Nickols CD, Whitwell HL. Neuropathology of inflicted head injury in children: II. Microscopic brain injury in infants. *Brain*. 2001;124(pt 7): 1299–1306
16. Ommaya AK, Goldsmith W, Thibault L. Biomechanics and neuropathology of adult and pediatric head injury. *Br J Neurosurg*. 2002; 16(3):220–242
17. Hymel KP, Makoroff KL, Laskey AL, Conaway MR, Blackman JA. Mechanisms, clinical presentations, injuries, and outcomes from inflicted versus noninflicted head trauma during infancy: results of a prospective, multicentered, comparative study. *Pediatrics*. 2007;119(5):922–929
18. Kelly P, McCormick J, Strange J. Non-accidental head injury in New Zealand: the outcome of referral to statutory authorities. *Child Abuse Negl*. 2009;33(6):393–401
19. Salehi-Had H, Brandt JD, Rosas AJ, Rogers KK. Findings in older children with abusive head injury: does shaken-child syndrome exist? *Pediatrics*. 2006;117(5). Available at: www.pediatrics.org/cgi/content/full/117/5/e1039
20. Jones R, Flaherty EG, Binns HJ, et al; Child Abuse Reporting Experience Study Research Group. Clinicians' description of factors influencing their reporting of suspected child abuse: report of the child abuse reporting experience study research group. *Pediatrics*. 2008;122(2):259–266
21. Penal code, Article 223–6. Available at: http://195.83.177.9/upl/pdf/code_33.pdf. Accessed June 15, 2010
22. Schnitzer PG, Ewigman B. Child deaths resulting from inflicted injuries: household risk factors and perpetrator characteristics. *Pediatrics*. 2005;116(5). Available at: www.pediatrics.org/cgi/content/full/116/5/e687
23. Starling SP, Holden JR, Jenny C. Abusive head trauma: the relationship of perpetrators to their victims. *Pediatrics*. 1995;95(2): 259–262
24. Christian CW, Block R; American Academy of Pediatrics, Committee on Child Abuse and Neglect. Abusive head trauma in infants and children. *Pediatrics*. 2009; 123(5):1409–1411
25. Lindberg DM, Lindsell CJ, Shapiro RA. Variability in expert assessments of child physical abuse likelihood. *Pediatrics*. 2008; 121(4). Available at: www.pediatrics.org/cgi/content/full/121/4/e945
26. American Academy of Pediatrics, Section on Radiology. Diagnostic imaging of child abuse. *Pediatrics*. 2009;123(5):1430–1435

Abusive Head Trauma: Judicial Admissions Highlight Violent and Repetitive Shaking

Catherine Adamsbaum, Sophie Grabar, Nathalie Mejean and Caroline Rey-Salmon

Pediatrics published online Aug 9, 2010;

DOI: 10.1542/peds.2009-3647

Updated Information & Services

including high-resolution figures, can be found at:
<http://www.pediatrics.org>

Permissions & Licensing

Information about reproducing this article in parts (figures, tables) or in its entirety can be found online at:
<http://www.pediatrics.org/misc/Permissions.shtml>

Reprints

Information about ordering reprints can be found online:
<http://www.pediatrics.org/misc/reprints.shtml>

American Academy of Pediatrics

DEDICATED TO THE HEALTH OF ALL CHILDREN™

